

VIII. *On the Structure of the Membrana Tympani in the Human Ear.* By JOSEPH TOYNBEE, F.R.S., Fellow of the Royal College of Surgeons of England, Aural Surgeon to St. Mary's Hospital, and Consulting Surgeon to the St. George's and St. James's General Dispensary.

Received June 19,—Read June 20, 1850.

IN conducting researches into the pathological condition of the organ of hearing, I have been impressed with the necessity of ascertaining, with as much precision as possible, the intimate structure of the various tissues entering into its composition. The results to which investigations undertaken with this latter object in view have led me, in reference to the structure of the membrana tympani, it is the purpose of the present paper to detail. It will be observed that the conclusions at which I have arrived, differ materially in various important particulars from those of previous investigators.

Examined from the exterior, inwards the membrana tympani consists of the following layers:—

1. The epidermis.
2. The proper fibrous layer, composed of—
  - a. The lamina of radiating fibres.
  - b. The lamina of circular fibres.
3. The mucous membrane (Plate III. fig. 1).

1. The *epidermis* is a thin layer covering the outer surface of the radiating fibrous lamina; it is continuous with the epidermis of the external meatus, and when subjected to the process of maceration it can be removed in the form of a small blind pouch, which presents, as it were, a cast of the meatus and of the external surface of the membrana tympani. When floating in water the pouch assumes the form it had when in contact with other tissues, and its internal extremity is convex, corresponding with the external concavity of the membrana tympani (fig. 2). The layer of epidermis forming the outermost coat of the membrana tympani is thin, and in the living subject so transparent that the radiating fibrous layer is distinctly seen through its substance: its outer surface is very smooth and capable of reflecting light: this layer presents no appearance of an orifice.

2. The *proper fibrous layer* of the membrana tympani can be easily separated into two laminæ, which, on account of the direction of their component fibres, may be called the radiating fibrous and the circular fibrous laminæ. Previous to entering upon an examination of these structures, it is desirable to cite the opinions which eminent anatomists have entertained on the subject.

In the Croonian Lecture, published in the nineteenth volume of the Philosophical Transactions, Sir EVERARD HOME advanced the opinion that the membrana tympani in the human subject was muscular. His words are, "When viewed in a microscope magnifying twenty-three times, the muscular fibres are beautifully conspicuous, and appear uniformly the same throughout the whole surface. There being no central tendon as in the diaphragm, the muscular fibres appear only to form the internal layer of the membrane, and are most distinctly seen when viewed on that side\*." The use of this radiated muscle, Sir EVERARD HOME states, is "to give those different degrees of tension to the membrane, which empower it to correspond with the variety of external tremors†." Since the first publication of this opinion as to the muscularity of the membrana tympani, anatomists have generally conceded that it is fibrous, but they have widely differed as to its composition. According to Mr. QUAIN and Dr. SHARPEY, "it is made up of fine closely arranged fibres, the greater number of which radiate from near the centre to the circumference; but within these are circular fibres which are more scattered and indistinct, except close to the margin of the membrane, where they form a dense, almost cartilaginous ring‡." Mr. WHARTON JONES writes, "The proper membrane can be divided into two layers, an outer thin one, consisting of radiating fibres, and an inner thicker layer, which is less distinctly fibrous, though when torn it does indicate a fibrous disposition, and that in a direction opposite to the former. . . . The fibres which cross the radiating ones are also more aggregated at the centre. They run parallel with the handle of the malleus and turn round its extremity. At the circumference of the proper membrane there is a thick firm ligamentous or cartilaginous ring, which is fixed in the groove of the bone. The ligamentous ring appears to be formed by an aggregation of the circular fibres interwoven with the peripheral extremities of the radiating ones§."

By careful dissection the fibrous layers of the membrana tympani may be separated into two distinct laminæ, the fibres of which have no communication with each other. The external layer may be called the *radiate fibrous lamina*, on account of its fibres radiating from the malleus to be attached to the cartilaginous ring, and the internal the *circular fibrous lamina*. The radiate layer is the thicker and stronger. So readily may the two layers be separated from each other, that they are detached with greater facility than that with which the circular layer can be removed from the mucous membrane.

#### a. *The Radiate Fibrous Lamina.*

If the whole of the membrana tympani be carefully removed, there will be observed at its circumference a white dense ring, apparently cartilaginous, which is received into the osseous groove of the temporal bone appropriated to it. It will be remembered however that this groove occupies only about five-sixths of the circumference of the inner extremity of the meatus, the upper sixth being smooth instead of grooved.

\* *Loc. cit.*, p. 5.

† P. 11.

‡ *Elements of Anatomy*, fifth edition, 1848, vol. ii. p. 932.

§ *Cyclopædia of Anatomy and Physiology*, vol. ii. p. 545.

The cartilaginous ring at the upper part is attached to the malleus, the anterior extremity being inserted into the anterior part of the cervix of this bone, and the posterior extremity into its posterior part; the outer surface of this ring has attached to it the periosteum, lining the external meatus (fig. 3). If the radiate lamina be examined with a magnifying power of ten or twelve diameters, fibres will be observed whose peripheries are attached to the cartilaginous ring, and their other extremities to the malleus. The uppermost of these fibres, however, must be excepted from the observation just made, for instead of passing from the superior part of the cartilaginous ring to the malleus, they take their course in front of the processus brevis and form a distinct layer of membrane covering its outer surface (fig. 3). The disposition of this portion of the radiating fibrous lamina is interesting alike to the anatomist and to the surgeon, for it is observed to be continuous with the periosteal lining of the upper part of the external meatus. Mr. SHRAPNELL, perceiving that this portion of the membrana tympani was not so tense as the rest, considered it to be a distinct structure, and named it the "membrana flaccida\*."

Directly below the processus brevis of the malleus the radiating fibres are attached to the ridge occupying the external surface of the bone, but at this part the fibres from each half of the membrana tympani are inserted so near to each other that no portion of the malleus is visible when viewed exteriorly; towards the inferior extremity of the long process, however, the fibres are attached to the sides and not to the anterior surface, and thus a small portion of the external surface of the long process at its inferior part is left bare and is in contact with the epidermoid layer, as may be distinctly seen in the healthy living ear by means of the speculum auris and a magnifying lens. The fibres extending from the malleus and forming the posterior segment of the membrane, are one-fourth longer than those forming the anterior segment. The thickest part of this layer is that which surrounds the extremity of the long process of the malleus, and the most attenuated is that which lies between the posterior margin of the long process of the malleus and the circumference of the membrana tympani†.

#### *Structure of the Radiate Lamina.*

The fibres composing the radiate lamina, when examined in a fresh state by the microscope, are translucent, and with the exception of a few transparent granules, present no peculiarity of structure; the longitudinal parallel wavy lines, characteristic of ordinary fibrous membranes, are absent. These fibres are flat, and vary from a 4000th to a 5000th part of an inch in breadth (fig. 5). In passing from the circular

\* Medical Gazette, vol. x.

† The blood-vessels ramifying in the upper part of the membranous lining of the external meatus are freely continuous with those of the membrana tympani. These blood-vessels are connected by cellular tissue, and the two together often form a distinct layer of membrane covering the outer surface of the upper part of the external radiate fibrous lamina (fig. 4). See Appendix.

cartilage to the malleus these fibres interlace with each other, from whence originates the peculiar diamond-shaped markings observable on the outer surface of the membrane (fig. 6). When treated with acetic acid this lamina becomes opaque, and sometimes elongated oval nuclei are observed, the long axes of which correspond with the course of the fibres (fig. 7). These nuclei are by no means invariably to be detected, and in several specimens they were not apparent on the application of the acid. In no instance was an oval nucleus visible in an isolated fibre.

The *circular white band* at the circumference of the radiate fibres consists of a firm mass of tissue, which is slightly elastic. It presents an indistinct appearance of fibres intermixed with oval-shaped nuclei. Upon the application of acetic acid this structure loses its white aspect, becomes translucent, and discloses a greater number of the oval nuclei (fig. 8).

#### b. *The Circular Fibrous Lamina.*

This membrane is attached to the radiating fibres by fine cellular tissue, and, as previously stated, the two structures can be separated with facility; the fibres of each lamina are quite distinct and never intermingle. The circular lamina consists, as its name implies, of circular fibres; they are firm and strong at its circumference, but towards the centre they are so attenuated as to be detected only by considerable care. The strong fibres at the circumference of the layer form a complete circle, and are attached to each side of the body of the malleus and to the sides of the upper third of the *processus longus* (fig. 9). When carefully examined by a magnifying power of thirty to forty diameters, these circular fibres are observed to be intersected by others of an extremely delicate character; these delicate fibres are more numerous towards the central part of the lamina, where they are so intimately blended with the circular fibres that the latter are not easily distinguished (fig. 10). The central thin portion of the circular lamina is not attached to the malleus, but the fibres from each side are continuous, and they form a membranous layer composed of a series of concentric fibrous circles. The outer surface of this central portion of the lamina is in contact with the inner surface of the lower half of the long process of the malleus, to which it is adherent by loose cellular tissue. The circular fibrous lamina is entirely unconnected with the cartilaginous ring into which the radiating fibres are inserted, but it is continuous with the periosteal lining of the tympanic cavity, of which it may be considered a modification. When the lamina of circular fibres is detached from that of the radiating fibres, it will be found to be slightly concave externally, though not to the same extent as the outer layer. In its separate condition it becomes rather less concave than when it was applied to the inner surface of the radiating fibres, and when its central portion is pressed inwards so as to increase its concavity, its inherent elasticity causes it quickly to resume its former shape, resembling that of a saucer. If the two layers be detached from each other and placed side by side, the greater degree of concavity externally of the radiating fibrous layer is very perceptible.

*Structure of the Circular Lamina.*

When highly magnified, the fibres composing the circular lamina are found to be smaller than those constituting the radiate fibrous layer; they vary in size from the 6000th to 10,000th of an inch in breadth. The outer fibres run parallel with each other, and do not interlace so much as the radiating fibres; they are diaphanous, and do not present any wavy longitudinal lines (fig. 11). When acetic acid is applied the fibres enlarge and assume a certain degree of opacity, and in some instances this lamina also has presented distinct oval nuclei, elongated in the direction of the fibres (fig. 12). Like the radiate lamina, the separate fibres were never observed to reveal the existence of nuclei, and as a general rule their presence in the tissue is not detected.

It is often not easy to decide whether a structure is muscular, and doubts may arise as to the real nature of the two fibrous laminæ of the membrana tympani. My own researches do not seem to favour the view of that membrane being a contractile tissue.

The facts which seem to militate against the idea of its being muscular are,—

1st. The absence of distinct nuclei in the fibres.

2nd. Their great denseness and hardness, their firm and unyielding structure, they being so strong that it is with some difficulty they can be torn across.

The *mucous membrane* forming the inner layer of the membrana tympani is in the healthy ear so extremely thin that its presence is with difficulty detected; by careful dissection however it can nevertheless be removed entire from the inner surface of the circular fibres, to which it is connected with considerable firmness by fine cellular tissue.

It will now be evident that of all the laminæ which constitute the membrana tympani not one is proper to the organ, all of them being directly continuous with other structures, of which they appear to be modifications\*. Thus:—

1st. The *epidermis* is continuous with that lining the external meatus.

2nd. The *radiate fibrous lamina* is a prolongation of the periosteal lining of the external meatus.

3rd. The *circular fibrous lamina* is a prolongation of the periosteum of the tympanum.

4th. The layer of *mucous membrane* forms part of the lining of the tympanic cavity (fig. 13).

Previous to considering the functions of the fibrous laminæ of the membrana tympani, it is desirable to advert to another point in the structure and relations of this organ. It has been already stated that the membrana tympani is attached at its circumference to the temporal bone, and at its central part to the malleus. The

\* See Appendix.

latter bone is so suspended by means of the *processus gracilis* and the short process of the *incus*\*, that the long process can move inwards towards the tympanic cavity, and outwards towards the meatus (fig. 14). It must be evident, therefore, that in order to prevent the concave *membrana tympani*, with the above attachments, from remaining in a state of relaxation, either the *tensor tympani* muscle must be in a state of continual contraction, or some other provision must exist for retaining the *membrana tympani* in the moderately tense condition fitting it to receive the sonorous undulations. The provision which actually exists, and which, so far as I am aware, has hitherto escaped the attention of anatomists, is the *tensor ligament of the membrana tympani*.

The ligament in question is about three-fourths of a line in length, and it is attached internally to the cochleariform process, and externally to that part of the inner surface of the malleus where the long process joins the neck (fig. 15). In the interior of this ligament, which presents a tubular shape, is placed the tendon of the *tensor tympani* muscle. It is thin anteriorly, where it consists of very delicate fibres, but the remainder is thick and dense, being composed of firm ligamentous tissue. So long as this ligament remains entire and the *membrana tympani* uninjured, the latter structure retains its natural degree of concavity and tenseness; but upon the ligament being cut through, or upon a solution of continuity being effected as the result of disease, the *membrana tympani* becomes very flaccid, even though the tendon of the *tensor tympani* muscle remains entire. In a preparation, when the *tensor tympani* muscle is pulled †, the *membrana tympani* is rendered very tense, and the *tensor tympani* ligament is relaxed; but immediately that the muscle is relaxed the *membrana tympani* is observed to return to its usual state, and the ligament is again rendered tense.

#### *On the Functions of the Fibrous Laminae of the Membrana Tympani.*

It is obvious that one use of the fibrous laminae of the *membrana tympani* is to present a firm but delicate membranous septum for the reception of sonorous undulations. The arrangement of the two sets of fibres at right angles to each other has

\* The short process of the *incus* is attached to the margin of the mastoid cells by ligamentous fibres, which allow of a lateral motion only.

† The *tensor tympani* muscle has an attachment which appears not to have been hitherto noticed. The tendon is generally described as passing backwards from the muscle, and then turning outwards over the cochleariform process to be attached to the malleus; but previously to changing its direction this tendon is very firmly attached by strong ligamentous tissue to the posterior extremity of the groove of the *tensor tympani* muscle (fig. 16). When the muscle contracts, these ligamentous fibres are put on the stretch, and the portion of the tendon that passes to the malleus being also stretched, the malleus is drawn in, and the *membrana tympani* rendered tense; but with whatever degree of force the muscle may afterwards be pulled, the *membrana tympani* itself is not rendered more tense in the slightest degree, the whole strain being on the above-described ligamentous fibres attached to the groove. If these fibres are cut through and the muscle be tightly drawn, the *membrana tympani* is ruptured.

the effect of imparting great strength to the membrane, while it preserves its extreme delicacy and tenuity. It has been stated that there is no evidence to prove that the fibres, of which the membrana tympani is composed, possess in themselves any contractile power; neither do the component fibres of the laminæ appear to evince more than an extremely slight degree of elasticity. An examination however of the structure after death shows that it has an inherent power of returning to its natural state of tension after being unusually distended. Thus, if the membrana tympani be exposed without interfering with its natural state of tension, and the canal containing the tensor tympani muscle be laid open, so that that muscle can be drawn towards its origin, the external concavity of the membrana tympani can be increased till it becomes very tense, but as soon as the muscle is let go the membrana tympani will be observed to resume its former condition. This action is explainable partly by the slight elasticity of the circular cartilaginous band, into which the peripheral extremities of the radiating fibres are inserted, and partly by the slight elasticity of these fibres themselves, but more especially by the peculiar arrangement of the circular fibrous lamina, which it will be remembered has always a tendency, when left to itself, to assume a more shallow form. Thus, when the membrane is rendered very concave, the circular fibres are slightly separated from each other; but when the extra tension ceases, the fibres intersecting the circular ones aid in drawing the latter together again.

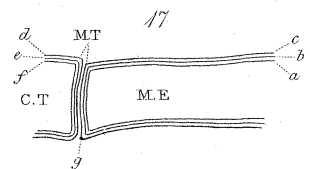
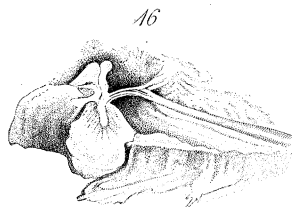
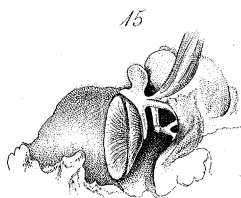
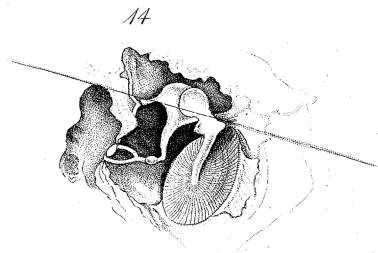
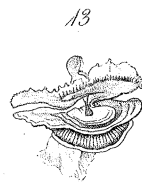
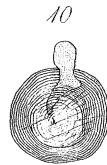
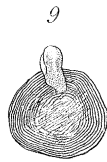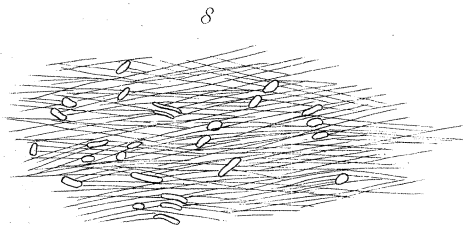


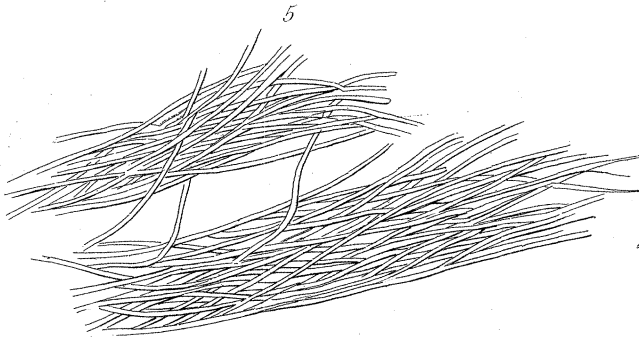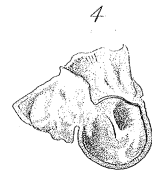
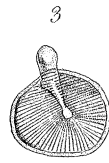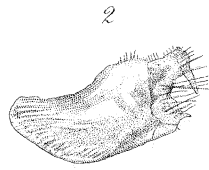
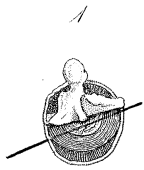
The disposition of the central part of the circular lamina also assists it in the function of bringing back the membrana tympani to its natural state after tension by the tensor tympani muscle. It has been stated that the middle part of these circular fibres, instead of being attached to the handle of the malleus, are applied against its inner surface, and thus the membrane is rendered tense by the pressure of the long process of the malleus against its outer surface during the action of the tensor tympani muscle, and when this muscle ceases to act the central part of the circular layer of fibres reacts on the malleus, and constrains it to resume its usual position. Besides the office of bringing the membrana tympani to its natural state after the action of the tensor tympani muscle, the circular fibrous layer would appear to be always acting as an antagonist to the tensor tympani ligament, and by the continued action of these two tissues, the one drawing it inwards, the other outwards, the membrana tympani is kept in a state adapted to receive all the ordinary sonorous undulations, independent of the exercise of any muscular power.

## EXPLANATION OF THE FIGURES.

## PLATE III.

- Fig. 1. The epidermoid layer having been removed by maceration, the two fibrous laminae and the mucous membrane are seen partially separated by dissection. (Natural size.)
- Fig. 2. The tubular cul-de-sac formed by the epidermis lining the external meatus; the inner extremity corresponding with the membrana tympani is convex. (Natural size.)
- Fig. 3. The radiate fibrous lamina of the membrana tympani; the fibres of which it is composed extend between the cartilaginous ring and the malleus, with the exception of the uppermost fibres, which are not inserted into the malleus. (Slightly magnified.)
- Fig. 4. The external surface of the membrana tympani, the epidermoid layer having been removed; the upper part of the membranous meatus is seen to be continuous with a membrane covering the upper and outer surface of the radiate fibrous lamina. [This membrane is the dermoid lamina of the membrana tympani; it is described in the Appendix to the paper as covering the whole of the outer surface of the radiating fibrous lamina.]
- Fig. 5. The fibres composing the radiate fibrous lamina. (Magnified about 300 diameters.)
- Fig. 6. The radiate fibrous lamina, external surface displaying the peculiar markings caused by the interlacement of the fibres. (Magnified about 300 diameters.)
- Fig. 7. The radiate fibrous lamina after having been treated with acetic acid.
- Fig. 8. The circular cartilaginous band after having been treated with acetic acid.
- Fig. 9. The external surface of the circular fibrous lamina; the fibres being attached to the processus longus of the malleus. (Slightly magnified.)
- Fig. 10. The internal surface of the circular fibrous lamina; the long process of the malleus is seen through the translucent central part. (Slightly magnified.)
- Fig. 11. The fibres composing the circular fibrous lamina. (Magnified about 300 diameters.)
- Fig. 12. The circular fibrous lamina after being treated with acetic acid.
- Fig. 13. The radiate fibrous lamina, the circular fibrous lamina and the mucous membrane of the membrana tympani seen to be continuous with other structures. (Slightly magnified.)
- Fig. 14. The attachment of the incus and malleus, illustrative of the movements of the incus, malleus and membrana tympani.
- Fig. 15. The attachments of the tensor tympani ligament; the tendon of the tensor tympani muscle is drawn upwards so as to expose the ligament.
- Fig. 16. The insertion of the tensor tympani muscle and its attachment by strong ligamentous fibres to the inner part of the base of the cochleariform process.





*Appendix to a Paper "On the Structure of the Membrana Tympani in the Human Ear."*

By JOSEPH TOYNBEE, F.R.S., Fellow of the Royal College of Surgeons of England, Aural Surgeon to St. Mary's Hospital, and Consulting Surgeon to the St. George's and St. James's General Dispensary.

IN a note at p. 161 of the above paper, I have stated that "the blood-vessels ramifying in the upper part of the membranous lining of the external meatus are freely continuous with those of the *membrana tympani*. These blood-vessels are connected by cellular tissue, and the two together often form a distinct layer of membrane, covering the outer surface of the upper part of the radiate fibrous lamina (fig. 4)." Since writing the above lines I have had opportunities of making several careful dissections of the membrane alluded to, and the result of these dissections is to demonstrate that between the epidermoid and radiating fibrous layers of the *membrana tympani*, there is a distinct and complete lamina of membrane which is continuous with the dermoid layer of the meatus. The presence of this membrane, to which, on account of its structure and functions, I have given the name of *dermoid layer*, is best demonstrated by carefully dissecting under water the membranous meatus from the upper surface of the osseous tube as far as the attachment of the *membrana tympani*; at this point the periosteum of the meatus is seen to become continuous with the radiate fibrous lamina; this being cut through, the dermoid layer is seen passing down over the outer surface of the radiate fibres, and separating them from the epidermis. If the upper portion of this layer be drawn gently downwards by one hand, by means of a fine needle in the other, the delicate cellular tissue connecting it to the fibrous lamina can be broken up and it may be removed entire. The presence of the dermoid lamina may also be shown by the introduction of a fine bristle between it and the radiating fibrous layer, at the superior part of the *membrana tympani*, and then by passing it down the cellular tissue is lacerated.

In a healthy state, when uninjected by blood or by artificial means, the dermoid lamina is thin and transparent; examined by the microscope its structure is found to resemble areolar tissue. When injected, this membrane is observed to have numerous blood-vessels ramifying through it, and they form an elaborate plexus; when these vessels are enlarged, they give the red appearance to the surface of the *membrana tympani* which is so frequently met with during life. It is upon the supply of nerves to this membrane that the exquisite sensibility of the *membrana tympani* depends.

A knowledge of the existence of the membrane here described is of interest to the anatomist, who recognizes in it the secreting organ of the epidermoid layer of the *membrana tympani*; and to the surgeon, who by its presence is able to understand phenomena occurring in certain diseases of the ear which have been hitherto incomprehensible to him. Figure 17 is illustrative of the structure of the *membrana tympani*,

and it shows that the six layers of which it is composed are continuous with adjacent tissues.

I may state in conclusion, that the opinion of the non-muscularity of the fibrous laminæ of the *membrana tympani* advanced in the above paper, has been confirmed by Dr. HARRISON of Dublin, in his dissection of the *membrana tympani* of the Elephant; he says, "I see no evidence of the muscular structure of the *membrana tympani*, so accurately described by Sir EVERARD HOME in the Philosophical Transactions, and mentioned by subsequent writers, who seem to have adopted his opinions rather than to have examined the organ for themselves\*."

*Explanation of figure 17, showing the six Laminæ composing the Membrana Tympani.*

A vertical section from without inwards of the meatus externus, *membrana tympani* and *cavitas tympani*.

M. E. Section of the meatus externus.

C. T. Section of the *cavitas tympani*.

M. T. Section of the *membrana tympani*.

*a.* The epidermis lining the meatus externus.

*b.* The dermoid layer of the meatus externus.

*c.* The periosteum of the meatus externus.

*d.* The periosteum of the tympanic cavity.

*e.* The mucous membrane of the tympanic cavity.

*f.* The epithelium of the tympanic cavity.

*g.* The circular fibro-cartilage of the *membrana tympani*.

\* Anatomical Observations on some Parts of the Elephant, by ROBERT HARRISON, M.D., Professor of Anatomy, Trinity College, Dublin. Proceedings of the Royal Irish Society, vol. iii.